

Cortical thinning and caudate abnormalities in first episode psychosis and their association with clinical outcome

Cathy Scanlon^{a,b}, Heike Anderson-Schmidt^{a,c}, Liam Kilmartin^d, Shane McInerney^a, Joanne Kenney^{a,b}, John McFarland^a, Mairead Waldron^{a,b}, Srinath Ambati^{a,b}, Anna Fullard^a, Sam Logan^a, Brian Hallahan^a, Gareth J. Barker^e, Mark A. Elliott^{f,b}, Peter McCarthy^g, Dara M. Cannon^{a,b}, Colm McDonald^{a,b}

Affiliation:

^aClinical Neuroimaging Laboratory, Departments of ^a Psychiatry and Anatomy, College of Medicine, Nursing and Health Sciences, National University of Ireland Galway, Galway, Ireland

^bNCBES Galway Neuroscience Center, National University of Ireland Galway, Galway, Ireland

^cDepartment of Psychiatry and Psychotherapy, Section of Psychiatric Genetics, University Medical Centre Goettingen, Georg-August University, Goettingen, Germany.

^dCollege of Engineering and Informatics, National University of Ireland Galway, Galway, Ireland.

^eKing's College London, Institute of Psychiatry, Department of Clinical Neuroscience, Centre for Neuroimaging Sciences, London, UK.

^fSchool of Psychology, National University of Ireland, Galway, Co. Galway, Ireland

^gDepartment of Radiology, College of Medicine, Nursing and Health Sciences, National University of Ireland Galway, Galway, Ireland

Corresponding Author:

Prof. Colm McDonald
Clinical Neuroimaging Laboratory
Department of Psychiatry
Clinical Science Institute
National University of Ireland, Galway
Galway
Ireland
Tel: +353-91-495465
Fax: +353-91-494563
e-mail: colm.mcdonald@nuigalway.ie

Abstract

First episode psychosis (FEP) has been associated with structural brain changes, largely identified by volumetric analyses. Advances in neuroimaging processing have made it possible to measure geometric properties that may identify subtle structural changes not appreciated by a measure of volume alone. In this study we adopt complementary methods of assessing the structural integrity of grey matter in FEP patients and assess whether these relate to patient clinical and functional outcome at 3 year follow-up.

1.5 Tesla T1-weighted Magnetic Resonance (MR) images were acquired for 46 patients experiencing their first episode of psychosis and 46 healthy controls. Cerebral cortical thickness and local gyrification index (LGI) were investigated using FreeSurfer software. Volume and shape of the hippocampus, caudate and lateral ventricles were assessed using manual tracing and spherical harmonics applied for shape description.

A cluster of cortical thinning was identified in FEP compared to controls; this was located in the right superior temporal gyrus, sulcus, extended into the middle temporal gyrus (lateral temporal cortex – LTC). Bilateral caudate volumes were significantly lower in FEP relative to controls and the right caudate also displayed regions of shape deflation in the FEP group. No significant structural abnormalities were identified in cortical LGI or hippocampal or lateral ventricle volume/shape. Neither LTC nor caudate abnormalities were related to change in symptom severity or global functioning 3 years later.

LTC and caudate abnormalities are present at the first episode of psychosis but do not appear to directly affect clinical or functional outcome.

Keywords: First episode psychosis, MRI, cortical thickness, volume, shape, superior temporal gyrus, caudate

1. Introduction

Studying psychosis at the first episode is optimal for examining the underlying neurobiology of the illness, as it removes confounders associated with the illness and its treatment, such as long-term medication use (Ho et al., 2011). Abnormalities such as ventricular enlargement and hippocampal and basal ganglia volume reduction have been reported in first episode schizophrenia (Ellison-Wright et al., 2008; Vita et al., 2006). However, patients experiencing the less specific first episode of psychosis (FEP) appear to have more subtle deficits, with a recent meta-analysis identifying reduced grey matter volume in the right superior temporal gyrus (STG), bilateral insula and cerebellum (Fusar-Poli et al., 2011b).

While the majority of previous studies have focused on brain tissue volumes, advances in neuroimaging data processing have made it possible to measure further geometric properties such as cortical thickness, cortical folding (gyrification) and the shape of brain structures, which may identify more subtle structural changes than volume alone (Ong et al., 2012; Scanlon et al., 2011). With advances in methodology, it is also possible to separate volume into its subcomponents of thickness and surface area on the cerebral cortex, properties that do not necessarily track each other (Dickerson et al., 2009). Cortical thinning has previously been identified in FEP in the superior temporal gyrus, prefrontal and occipital cortex (Janssen et al., 2009).

Gyrification is the measure of the amount of cortex buried within the sulcal folds as compared with the amount of visible cortex. Gyrification of the brain undergoes substantial development during foetal life and as such can be a useful marker of cortical development later in life (Rajagopalan et al., 2011) and may reflect disturbances in connectivity (Ronan et al., 2011). A recent study in FEP patients identified hypogyrification across multiple brain regions and found that patients with poor treatment response displayed more prominent abnormalities (Palaniyappan et al., 2013).

Abnormalities of subcortical structures have been reported in FEP, with caudate nucleus volume loss being a consistent finding in first episode schizophrenia (Ellison-Wright et al., 2008). Conversely, hippocampal volume loss has been more often implicated in chronic schizophrenia rather than at the first episode (Ellison-Wright et al., 2008). Quantifying an overall measure of brain structure volume however may not be sensitive to local regional changes in structural integrity which may be better detected by analysis of shape (Ong et al., 2012).

Recent evidence has suggested that volumetric abnormalities at the time of first episode may be used to identify those patients who will have the poorest clinical outcome (Lappin et al. 2013; Mourao-Miranda et al., 2012). In the current study we sought to determine if abnormal neuroimaging findings at FEP are predictive of clinical outcome 3 years later. Using a range of complimentary morphological Magnetic Resonance Imaging (MRI) analysis methods, this study aims 1) to identify the morphometric abnormalities in patients experiencing their first episode of psychosis and 2) to determine if identified abnormalities are related to clinical outcome 3 years later.

2. Methods

2.1 Subjects

Forty-six patients experiencing their first episode of psychosis and 46 healthy controls (HC) matched for age and gender participated in this study (Table 1). The baseline recruitment and clinical assessments have been described in detail previously (McFarland et al., 2012). Exclusion criteria for all participants included neurological disorders, learning disability, lifetime substance dependency (as defined by DSM-IV-TR), a history of head injury resulting in loss of consciousness for over 5 minutes, oral steroid use in the previous 3 months and general contraindications to MRI. Healthy controls were also excluded if they had a personal history of any psychiatric illness, or a known family history of psychotic illness. Written informed consent was obtained from all participants. The study was approved by the Research Ethics Committees of the National University of Ireland Galway and Galway University Hospital.

2.2 Clinical assessment

Patients were diagnosed using the Structured Clinical Interview for DSM-IV-TR Research Version (First et al., 2002). FEP was defined as the presence of at least one psychotic symptom (e.g. delusions, hallucinations, disorder of thinking, disorganised/ bizarre behaviour). Patients were diagnosed with schizophrenia (n=15), schizoaffective- (n=4), schizophreniform (n=5), or delusional-disorder (n=3), mania (n=9), psychotic depression (n=6), psychosis Not Otherwise Specified (n=4). All patients were scanned as soon as was feasible after illness onset, and no more than 8 weeks after commencing any antipsychotic medication, with a median antipsychotic administration of 14 days. Seven patients were neuroleptic naïve and not taking any other medication at the time of scan, all other patients were taking an atypical antipsychotic. All patients underwent an assessment of symptomatology using the 0-6 point Positive and Negative Syndrome Scale (PANSS) (Kay et al., 1987) and a Global Assessment of functioning Score (GAF) (Hall, 1995). Duration of Untreated Psychosis (DUP) was measured using the Beiser Scale (Beiser et al., 1993). Total antipsychotic medication taken was recorded and converted to chlorpromazine (CPZ) equivalents (Lehman et al., 1998; Taylor et al., 2007; Woods, 2003) (Table 1).

PANSS and GAF were acquired 3.5 years later (SD=0.9 years) in 28 patients. Additionally, clinical notes of 34 patients were reviewed 3 years later and usual symptom severity (USS) assessed using an amended version of the WHO Life Chart Schedule (WHO, 1992) and rated according to a Likert rating scale: 0 = No further episodes, 1= Mild, 2= Moderate, 3=Severe. Figure 1 presents an overview of the patients re-recruited and lost to follow-up for each method.

2.3 MRI acquisition

All subjects underwent MR imaging at University Hospital Galway (UHG) in a 1.5 Tesla Siemens Magnetom Symphony scanner (Erlangen, Germany) equipped with a 4-channel head coil. A volumetric T1-weighted magnetization-prepared rapid acquisition of gradient echo (MPRAGE) sequence was acquired with the imaging parameters: Repetition time (TR): 1140ms, Echo time (TE): 4.38ms, Inversion Time (TI): 600ms, flip angle 15; matrix size 256 x 256; an in-plane pixel size of 0.9mm x 0.9mm and slice thickness 0.9mm.

2.4 Image Processing - Cortex Thickness and LGI

T1 images were intensity homogeneity corrected using nonparametric, non-uniform intensity normalization (N3) (Sled et al., 1998). Image processing and analysis of cortical thickness and local gyrification index (LGI) were carried out using FreeSurfer (FS), stable version 5.1 (<https://surfer.nmr.mgh.harvard.edu>). Detailed descriptions of this method have already been described (Dale et al., 1999; Fischl B, 1999), but are briefly summarised in the supplementary material (Supplementary Material 1).

2.5 Image Processing – Subcortical volume and shape

After intensity homogeneity correction using N3, T1-weighted images were skull-stripped using FSL's brain extraction tool (Smith, 2002) and aligned to the MNI template using a 6-parameter rigid body transformation. Hippocampus and caudate nucleus structures were segmented manually by trained raters who were blinded to diagnosis and according to a strict anatomical protocol using ITKsnap software (Yushkevich et al., 2006). Inter and intra-rater reliabilities were assessed on 10 randomly selected subjects using the intra-class correlation coefficient (ICC). Lateral ventricles were first automatically segmented using FreeSurfer software (Fischl et al., 2002) and then edited manually by a trained rater. Anatomical guidelines are available in Supplementary material (Supplementary Material 2).

A spherical harmonic (SPHARM) expansion technique was used to model the shape of each individual brain structure. This was carried out using Spharm-mat (Shen et al., 2009), implemented in the Matlab package (version 7.5) (Supplementary Material 3). In brief, alignment to an average template is carried out twice; once aligning subjects to the template without normalisation, which preserves the volume of the brain structure. Second, structures are normalised to the template, removing the effect of volume so that structure shape can be analysed independent of volume. At each point on the surface, the Euclidean distance was calculated between the subject and the template. Signed displacement maps are generated which calculates if the subject surface element lies inside (deflation) or outside (expansion) the template surface (positive displacements lie outside the template). Surfaces were smoothed using a 5-mm FWHM 2-D Gaussian kernel.

2.6 Statistical Analysis

A general linear model was used to investigate the effect of group (FEP or HC) on hippocampal, caudate and ventricular volumes, controlling for age and intracranial volume (ICV).

Surface-based statistical analysis was carried out using SurfStat for subcortical structures (Chung et al., 2010) and QDEC ("Query, Design, Estimate, Contrast") in FreeSurfer for cortical surface measures. Linear regression was performed to determine the effect of "group" on the measurement parameter at each surface vertex controlling for age. False discovery rate (FDR, $p=0.05$) was implemented for multiple comparisons correction. Identified clusters were extracted and averaged for the analysis of association with clinical variables.

Linear and logistic regression was utilised to determine if identified baseline brain abnormalities were related to DUP, GAF and CPZ equivalents at baseline; and to change in GAF, total PANSS and negative PANSS scores, USS at follow-up and an affective or non-

affective diagnosis (in those individuals with follow-up clinical assessments). Clinical variables were log transformed to normalise the data before analysis. Age and intracranial volume (ICV), included for measures of volume only were added as covariates.

3. Results

3.1 Cortical Analysis

A cluster of cortical thinning in the FEP group was identified in the right STG and sulcus extending into the middle temporal gyrus (lateral temporal cortex – LTC) (Figure 2). No cortical thickening was found in FEP participants compared with HCs.

No LGI differences were identified between patients and controls after correction for multiple comparisons.

3.2 Subcortical Analysis

Inter and intra-rater reliabilities produced ICC > 0.8 for hippocampus and caudate nucleus volume and > 0.9 for lateral ventricle volumes.

Volumetric results are displayed in Table 2. Both left and right caudate volumes were significantly lower in FEP participants (Table 2). In relation to regional volume changes, a large cluster was identified extending the length of the superior surface in bilateral caudate with the maximum t-statistic located at the anterior posterior portion of the caudal head in both instances (Figure 3). After normalisation to remove the effect of volume, the right caudate showed regions of shape deflation in the FEP group (Figure 3).

There was no significant difference between HC and FEP for overall left or right hippocampal or lateral ventricle volume. After correction for multiple comparisons there was no significant difference between controls and FEP for regional volume or shape changes.

3.3 Clinical Correlates

The identified abnormalities in the LTC and caudate nucleus were not associated with GAF, DUP or cumulative medication dose (as measured by CPZ equivalents). Caudate volumes were totalled to reduce multiple comparisons. Baseline caudate volume and LTC thickness at first episode did not predict Total PANSS, PANSS Negative, GAF, USS or affective/non-affective diagnosis (Table 3).

There were no significant differences in DUP, PANSS or GAF baseline scores between those successfully rerecruited for clinical assessment (n=28) and those who were lost to follow-up (n=18). Patients whose charts were unavailable for follow up (n=12) had significantly lower baseline PANSS-total (p=0.012), PANSS-neg (p=0.048) and PANSS-gen (p=0.018) scores compared to those still in the clinical system 3.5 years later (n=34).

Thirteen out of 28 patients changed diagnosis upon re-assessment 3.5 year later (Table 4).

3.4 Post-hoc analyses

A post-hoc analysis with gender included as a covariate did not change the reported results. A gender x group interaction was also investigated and the findings were similarly not significant. There were no significant volumetric differences between patients diagnosed with an affective disorder versus a non-affective disorder.

4. Discussion

This study identified volume reduction and shape deflation in the caudate bilaterally and thinning of the right LTC in FEP patients when compared with healthy controls. These morphometric abnormalities were not associated with cumulative antipsychotic medication, DUP or global functioning at baseline, nor predictive of patient outcome or change in illness course as assessed by PANSS, GAF and USS 3 years later.

4.1 Cerebral Cortex

The results of the current study are consistent with a previous study in FEP reporting cortical thinning in the right LTC, specifically the STG (Janssen et al., 2009). Further studies, also identifying right STG thinning, have specifically investigated first episode schizophrenia (Gutiérrez-Galve et al., 2010; Schultz et al., 2010b) or schizophrenia spectrum disorders (Crespo-Facorro et al., 2010). Both Schultz et al. (2010b) and Crespo-Facorro et al. (2007) identified more widespread thinning beyond the STG, affecting the frontal and occipital cortices, which may suggest that these additional regions are specific to schizophrenia type disorders. This is supported by a recent study identifying more extensive cortical thinning in schizophrenia than bipolar 1 patients (Rimol et al., 2012). More widespread thinning in prefrontal and right occipital cortex was also reported in a sample of adolescent males with FEP by Janssen et al. (2009).

In two recent meta-analyses of voxel-based volumetric studies in FEP, STG and insular volume loss were identified (Fusar-Poli et al., 2011b; Radua et al., 2012). Others identified right (Witthaus et al., 2009) and bilateral (Takahashi et al., 2010) STG reduction in individuals at ultra-high risk of psychosis (UHR), and a recent meta-analysis associated STG volume reduction with transition from UHR to psychosis (Fusar-Poli et al., 2011a). Our study also supports STG volume loss as an early morphometric marker in psychosis. A follow-up study of the patients in the current study would help ascertain if cortical thinning spreads frontally as the illness advances as has been proposed elsewhere (Thompson et al., 2001). The finding of LTC thinning present in this study on the right side only is also consistent with the theory of psychosis as a disturbance of lateralisation (Crow et al. 2013).

We were unable to replicate the finding of hypogyrfication in FEP identified by a recent study (Palaniyappan et al., 2013), which employed a larger sample size. The literature on gyrification in chronic schizophrenia is inconclusive, with previous studies showing increased gyrification in the right parahippocampal-lingual cortex region in first episode schizophrenia (Schultz et al., 2010a), while others have found reduced gyrification in prefrontal cortex (Palaniyappan et al., 2011; Ronan et al., 2012).

4.2 Sub-cortical findings

A bilateral volume reduction in the overall caudate is also consistent with previous studies of first episode schizophrenia (Ebdrup, 2010; Ellison-Wright et al., 2008; Haijma et al., 2012), although this finding did not emerge from a recent meta-analysis examining Voxel Based Morphometry (VBM) studies in FEP (Fusar-Poli et al., 2011b). Standard VBM analysis however may not be as sensitive to subtle changes in brain morphometry as other methods (Bergouignan et al., 2009; Scanlon et al., 2011). In the current study, using surface based analysis, we localised the largest decrease to the head of the caudate bilaterally, progressing posteriorly along the superior aspect. Haijma et al. (2012) showed that

reductions in caudate volume were more pronounced in anti-psychotic naïve compared to medicated schizophrenia patients, suggesting that this normalisation effect may be due to antipsychotic medication.

No hippocampal volume or shape abnormalities were identified in FEP patients in this study. Although reduced hippocampal volume has been a common finding in studies examining chronic schizophrenia (Ellison-Wright et al., 2008; Haijma et al., 2012), there is conflicting evidence of hippocampal volume loss in first episode schizophrenia (Borgwardt et al., 2007; Ebdrup, 2010; Vita et al., 2006). One recent study identified hippocampal volume reduction in first episode schizophrenia but not in first episode affective psychosis subjects (de Castro-Manglano et al., 2011).

The lateral ventricle volumes were not significantly different in FEP in the current study. Although the left lateral ventricle showed a trend towards enlargement, there was much variability in this structure volume. This non-significant result is reflected in some previous studies and meta analyses in first episode schizophrenia (Ebdrup, 2010; Kempton et al., 2010), with longitudinal studies suggesting progressive enlargement occurring after the first episode (Kempton et al., 2010) and especially within the first year of illness (Cahn et al., 2006).

4.3 Clinical Correlates and predictors

In this study, LTC or caudate abnormalities were not associated with cumulative antipsychotic medication dose, DUP or GAF scores at baseline. A shorter DUP has been shown to be related to a greater response to medication in FEP (Perkins et al., 2005) and although Keshavan et al. (1998) reported an inverse relationship between DUP and left superior temporal gyrus volume, our results are in agreement with a more recent study and a meta-analysis identifying no association with brain structure volume (Ebdrup, 2010; Fusar-Poli et al., 2011b). In contrast, non-affective psychosis patients with a longer DUP were noted to have smaller caudate volume (Crespo-Facorro et al., 2007). As a post-hoc analysis, we re-analysed the data with only the non-affective patients (n=30) but still did not observe a significant effect.

Patient GAF scores significantly improved and PANSS scores significantly reduced in the 3.5 year follow-up period, however, baseline brain abnormalities did not predict functional outcome or symptom severity in this study. These results are in agreement with a large multicentre first episode schizophrenia study with a 2 year follow up period (Van Haren et al., 2003). Cahn et al. (2006), and more recently, Lappin et al. (2013) found that longitudinal changes in brain volume predicted GAF scores after 5 and 6 year follow up respectively. These studies suggest that longitudinal neuroimaging may be better predictors of functional outcome at follow-up.

4.4 Strengths and limitations

The strengths of this study include the cohort of early-onset psychosis patients with minimum exposure to antipsychotic medication, the availability of patient clinical and functional follow-up information to determine if baseline neuroimaging could predict patient outcome and image analysis methods applied in an effort to identify subtle shape and thickness changes not appreciated by an analysis of volume alone.

Limitations to this study include: 1. a modest sample size of 46 patients, which may

potentially reduce the statistical power to detect more subtle abnormalities; 2. the sample of FEP patients, although diagnostically typical of patients presenting with their first episode of psychosis, resulted in a clinically more heterogeneous sample than that of a tailored sample of schizophrenia patients 3. a number of sub-cortical brain structures were not investigated, including the thalamus implicated in first episode schizophrenia previously; 4. although we did not find that baseline brain abnormalities predicted symptom severity at follow-up, other variables at follow-up may be better suited for this purpose 5. a loss to clinical follow-up of approximately 35% was present.

4.5 Conclusion

In this cohort of individuals with FEP at a very early stage of their illness and with minimal medication exposure, subtle changes in the right LTC and bilateral caudate were already detectable, suggesting that these structures are affected early in the psychosis process. These MRI abnormalities however are not associated with poorer clinical course or outcome at 3 year follow-up.

References

- Beiser, M., Erickson, D., Fleming, J.A., Iacono, W.G. 1993. Establishing the onset of psychotic illness. *The American journal of psychiatry* 150, 1349-1354.
- Bergouignan, L., Chupin, M., Czechowska, Y., Kinkingn hun, S., Lemogne, C.d., Le Bastard, G., Lepage, M., Garnero, L., Colliot, O., Fossati, P., 2009. Can voxel based morphometry, manual segmentation and automated segmentation equally detect hippocampal volume differences in acute depression? *Neuroimage* 45, 29-37.
- Borgwardt, S.J., Riecher-Rössler, A., Dazzan, P., Chitnis, X., Aston, J., Drewe, M., Gschwandtner, U., Haller, S., Pflüger, M., Rechsteiner, E., D'Souza, M., Stieglitz, R.-D., Radü, E.-W., McGuire, P.K., 2007. Regional Gray Matter Volume Abnormalities in the At Risk Mental State. *Biological Psychiatry* 61, 1148-1156.
- Cahn, W., van Haren, N.E.M., Pol, H.E.H., Schnack, H.G., Caspers, E., Laponder, D.A.J., Kahn, R.S., 2006. Brain volume changes in the first year of illness and 5-year outcome of schizophrenia. *The British Journal of Psychiatry* 189, 381-382.
- Chung, M.K., Worsley, K.J., Nacewicz, B.M., Dalton, K.M., Davidson, R.J., 2010. General multivariate linear modeling of surface shapes using SurfStat. *Neuroimage* 53, 491-505.
- Crespo-Facorro, B., Roiz-Santiáñez, R., Pelayo-Terán, J.M., González-Blanch, C., Pérez-Iglesias, R., Gutiérrez, A., de Lucas, E.M., Tordesillas, D., Vázquez-Barquero, J.L., 2007. Caudate nucleus volume and its clinical and cognitive correlations in first episode schizophrenia. *Schizophrenia Research* 91, 87-96.
- Crespo-Facorro, B., Roiz-Santiáñez, R., Pérez-Iglesias, R., Rodríguez-Sánchez, J.M., Mata, I., Tordesillas-Gutiérrez, D., Sánchez, E., Tabarés-Seisdedos, R., Andreasen, N., Magnotta, V., Vázquez-Barquero, J.L., 2010. Global and regional cortical thinning in first-episode psychosis patients: relationships with clinical and cognitive features. *Psychological Medicine* 41, 1449-1460.
- Crow T.J., Chance S.A., Priddle T.H., Radua J., James AC., 2013. Laterality interacts with sex across the schizophrenia/bipolarity continuum: An interpretation of meta-analyses of structural MRI. *Psychiatry Research*. 210, 1232-1244.
- Dale, A.M., Fischl, B., Sereno, M.I., 1999. Cortical surface-based analysis: I. Segmentation and surface reconstruction. *Neuroimage* 9, 179-194.
- de Castro-Manglano, P., Mechelli, A., Soutullo, C., Landecho, I., Gimenez-Amaya, J.M., Ortuño, F., McGuire, P., 2011. Structural brain abnormalities in first-episode psychosis: differences between affective psychoses and schizophrenia and relationship to clinical outcome. *Bipolar Disorders* 13, 545-555.
- Dickerson, B.C., Feczko, E., Augustinack, J.C., Pacheco, J., Morris, J.C., Fischl, B., Buckner, R.L., 2009. Differential effects of aging and Alzheimer's disease on medial temporal lobe cortical thickness and surface area. *Neurobiology of Aging* 30, 432-440.
- Ebdrup, B., 2010. Hippocampal and caudate volume reductions in antipsychotic-naïve first-episode schizophrenia. *Journal of Psychiatry and Neuroscience* 35, 95-104.
- Ellison-Wright, I., Glahn, D.C., Laird, A.R., Thelen, S.M., Bullmore, E., 2008. The Anatomy of First-Episode and Chronic Schizophrenia: An Anatomical Likelihood Estimation Meta-

Analysis. *American Journal of Psychiatry* 165, 1015-1023.

First, M.B., Spitzer, R.L., Gibbon, M., Williams, J.B., 2002. Structured clinical interview for DSM-IV-TR axis I disorders, research version, patient edition. New York: Biometrics Research, New York State Psychiatric Institute.

Fischl, B., Salat, D.H., Busa, E., Albert, M., Dieterich, M., Haselgrove, C., van der Kouwe, A., Killiany, R., Kennedy, D., Klaveness, S., 2002. Whole brain segmentation: automated labeling of neuroanatomical structures in the human brain. *Neuron* 33, 341-355.

Fischl B, S.M., Dale AM., 1999. Cortical surface-based analysis II: inflation, flattening, and a surface-based coordinate system. *Neuroimage* 9, 195–207.

Fusar-Poli, P., Borgwardt, S., Crescini, A., Deste, G., Kempton, M.J., Lawrie, S., Mc Guire, P., Sacchetti, E., 2011a. Neuroanatomy of vulnerability to psychosis: A voxel-based meta-analysis. *Neuroscience & Biobehavioral Reviews* 35, 1175-1185.

Fusar-Poli, P., Radua, J., McGuire, P., Borgwardt, S., 2011b. Neuroanatomical Maps of Psychosis Onset: Voxel-wise Meta-Analysis of Antipsychotic-Naive VBM Studies. *Schizophrenia Bulletin* 38, 1297-1307.

Gutiérrez-Galve, L., Wheeler-Kingshott, C.A.M., Altmann, D.R., Price, G., Chu, E.M., Leeson, V.C., Lobo, A., Barker, G.J., Barnes, T.R.E., Joyce, E.M., Ron, M.A., 2010. Changes in the Frontotemporal Cortex and Cognitive Correlates in First-Episode Psychosis. *Biological Psychiatry* 68, 51-60.

Haijma, S.V., Van Haren, N., Cahn, W., Koolschijn, P.C.M., Pol, H.E.H., Kahn, R.S., 2012. Brain volumes in schizophrenia: a meta-analysis in over 18 000 subjects. *Schizophrenia Bulletin* 39, 1129-1138.

Hall, R.C., 1995. Global assessment of functioning: a modified scale. *Psychosomatics* 36, 267-275.

Ho, B.-C., Andreasen, N.C., Ziebell, S., Pierson, R., Magnotta, V., 2011. Long-term antipsychotic treatment and brain volumes: a longitudinal study of first-episode schizophrenia. *Archives of General Psychiatry* 68, 128-137.

Janssen, J., Reig, S., Alemán, Y., Schnack, H., Udias, J.M., Parellada, M., Graell, M., Moreno, D., Zabala, A., Balaban, E., Desco, M., Arango, C., 2009. Gyral and Sulcal Cortical Thinning in Adolescents with First Episode Early-Onset Psychosis. *Biological Psychiatry* 66, 1047-1054.

Kay, S.R., Fiszbein, A., Opfer, L.A., 1987. The positive and negative syndrome scale (PANSS) for schizophrenia. *Schizophrenia Bulletin* 13, 261-276.

Kempton, M.J., Stahl, D., Williams, S.C.R., DeLisi, L.E., 2010. Progressive lateral ventricular enlargement in schizophrenia: A meta-analysis of longitudinal MRI studies. *Schizophrenia Research* 120, 54-62.

Keshavan, M.S., Haas, G.L., Kahn, C.E., Aguilar, E., Dick, E.L., Schooler, N.R., Sweeney, J.A., Pettegrew, J.W., 1998. Superior temporal gyrus and the course of early schizophrenia: Progressive, static, or reversible? *Journal of Psychiatric Research* 32, 161-167.

Lappin, J., Morgan, C., Chalavi, S., Morgan, K., Reinders, A., Fearon, P., Heslin, M., Zanelli, J., Jones, P., Murray, R., 2013a. Bilateral hippocampal increase following first-episode psychosis is associated with good clinical, functional and cognitive outcomes. *Psychological*

Medicine, 1-13.

Lehman, A.F., Steinwachs, D.M., Dixon, L.B., Postrado, L., Scott, J.E., Fahey, M., Fischer, P., Hoch, J., Kasper, J.A., Lyles, A., 1998. Patterns of usual care for schizophrenia: initial results from the Schizophrenia Patient Outcomes Research Team (PORT) Client Survey. *Schizophrenia Bulletin* 24, 11-20.

McFarland, J., Cannon, D.M., Schmidt, H., Ahmed, M., Hehir, S., Emsell, L., Barker, G., McCarthy, P., Elliott, M.A., McDonald, C., 2012. Association of grey matter volume deviation with insight impairment in first-episode affective and non-affective psychosis. *European Archives of Psychiatry and Clinical Neuroscience* 263, 133-141.

Mourao-Miranda, J., Reinders, A., Rocha-Rego, V., Lappin, J., Rondina, J., Morgan, C., Morgan, K., Fearon, P., Jones, P., Doody, G., 2012. Individualized prediction of illness course at the first psychotic episode: a support vector machine MRI study. *Psychological Medicine* 42, 1037-1047.

Ong, D., Walterfang, M., Malhi, G.S., Styner, M., Velakoulis, D., Pantelis, C., 2012. Size and shape of the caudate nucleus in individuals with bipolar affective disorder. *Australian and New Zealand Journal of Psychiatry* 46, 340-351.

Palaniyappan, L., Mallikarjun, P., Joseph, V., White, T.P., Liddle, P.F., 2011. Folding of the prefrontal cortex in schizophrenia: regional differences in gyrification. *Biological Psychiatry* 69, 974-979.

Palaniyappan, L., Marques, T.R., Taylor, H., Handley, R., Mondelli, V., Bonaccorso, S., Giordano, A., McQueen, G., DiForti, M., Simmons, A., 2013. Cortical Folding Defects as Markers of Poor Treatment Response in First-Episode Psychosis. *JAMA Psychiatry* [Epub ahead of print].

Perkins, D.O., Gu, H., Boteva, K., Lieberman, J.A., 2005. Relationship between duration of untreated psychosis and outcome in first-episode schizophrenia: a critical review and meta-analysis. *American Journal of Psychiatry* 162, 1785-1804.

Radua, J., Borgwardt, S., Crescini, A., Mataix-Cols, D., Meyer-Lindenberg, A., McGuire, P.K., Fusar-Poli, P., 2012. Multimodal meta-analysis of structural and functional brain changes in first episode psychosis and the effects of antipsychotic medication. *Neuroscience & Biobehavioral Reviews* 36, 2325-2333.

Rajagopalan, V., Scott, J., Habas, P.A., Kim, K., Corbett-Detig, J., Rousseau, F., Barkovich, A.J., Glenn, O.A., Studholme, C., 2011. Local tissue growth patterns underlying normal fetal human brain gyrification quantified in utero. *The Journal of Neuroscience* 31, 2878-2887.

Rimol, L.M., Nesvåg, R., Hagler, D.J., Bergmann, Ø., Fennema-Notestine, C., Hartberg, C.B., Haukvik, U.K., Lange, E., Pung, C.J., Server, A., Melle, I., Andreassen, O.A., Agartz, I., Dale, A.M., 2012. Cortical Volume, Surface Area, and Thickness in Schizophrenia and Bipolar Disorder. *Biological Psychiatry* 71, 552-560.

Ronan, L., Pienaar, R., Williams, G., Bullmore, E., Tim, J., Roberts, N., Jones, P.B., Suckling, J., Fletcher, P.C., 2011. Intrinsic curvature: a marker of millimeter-scale tangential cortico-cortical connectivity? *International journal of neural systems* 21, 351-366.

Ronan, L., Voets, N., Hough, M., Mackay, C., Roberts, N., Suckling, J., Bullmore, E., James, A., Fletcher, P.C., 2012. Consistency and interpretation of changes in millimetre-scale cortical intrinsic curvature across three independent datasets in schizophrenia. *Neuroimage*

63, 611-621.

Scanlon, C., Mueller, S.G., Tosun, D., Cheong, I., Garcia, P., Barakos, J., Weiner, M.W., Laxer, K.D., 2011. Impact of Methodologic Choice for Automatic Detection of Different Aspects of Brain Atrophy by Using Temporal Lobe Epilepsy as a Model. *American Journal of Neuroradiology* 32, 1669-1676.

Schultz, C.C., Koch, K., Wagner, G., Roebel, M., Nenadic, I., Gaser, C., Schachtzabel, C., Reichenbach, J.R., Sauer, H., Schlösser, R.G., 2010a. Increased parahippocampal and lingual gyrification in first-episode schizophrenia. *Schizophrenia Research* 123, 137-144.

Schultz, C.C., Koch, K., Wagner, G., Roebel, M., Schachtzabel, C., Gaser, C., Nenadic, I., Reichenbach, J.R., Sauer, H., Schlösser, R.G.M., 2010b. Reduced cortical thickness in first episode schizophrenia. *Schizophrenia Research* 116, 204-209.

Shen, L., Farid, H., McPeck, M.A., 2009. Modeling Three-Dimensional Morphological Structures Using Spherical Harmonics. *Evolution* 63, 1003-1016.

Sled, J.G., Zijdenbos, A.P., Evans, A.C., 1998. A nonparametric method for automatic correction of intensity nonuniformity in MRI data. *Medical Imaging, IEEE Transactions on* 17, 87-97.

Smith, S.M., 2002. Fast robust automated brain extraction. *Human brain mapping* 17, 143-155.

Takahashi, T., Wood, S.J., Yung, A.R., Walterfang, M., Phillips, L.J., Soulsby, B., Kawasaki, Y., McGorry, P.D., Suzuki, M., Velakoulis, D., Pantelis, C., 2010. Superior temporal gyrus volume in antipsychotic-naive people at risk of psychosis. *The British Journal of Psychiatry* 196, 206-211.

Taylor, D.A., Paton, C., Kerwin, R., 2007. *Maudsley prescribing guidelines*. CRC Press.

Thompson, P.M., Vidal, C., Giedd, J.N., Gochman, P., Blumenthal, J., Nicolson, R., Toga, A.W., Rapoport, J.L., 2001. Mapping adolescent brain change reveals dynamic wave of accelerated gray matter loss in very early-onset schizophrenia. *Proceedings of the National Academy of Sciences* 98, 11650-11655.

Van Haren, N.E.M., Cahn, W., Hulshoff Pol, H.E., Schnack, H.G., Caspers, E., Lemstra, A., Sitskoorn, M.M., Wiersma, D., van den Bosch, R.J., Dingemans, P.M., Schene, A.H., Kahn, R.S., 2003. Brain volumes as predictor of outcome in recent-onset schizophrenia: a multi-center MRI study. *Schizophrenia Research* 64, 41-52.

Vita, A., De Peri, L., Silenzi, C., Dieci, M., 2006. Brain morphology in first-episode schizophrenia: A meta-analysis of quantitative magnetic resonance imaging studies. *Schizophrenia Research* 82, 75-88.

Witthaus, H., Kaufmann, C., Bohner, G., Özgürdal, S., Gudlowski, Y., Gallinat, J., Ruhrmann, S., Brüne, M., Heinz, A., Klingebiel, R., Juckel, G., 2009. Gray matter abnormalities in subjects at ultra-high risk for schizophrenia and first-episode schizophrenic patients compared to healthy controls. *Psychiatry Research: Neuroimaging* 173, 163-169.

Woods, S.W., 2003. Chlorpromazine equivalent doses for the newer atypical antipsychotics. *Journal of Clinical Psychiatry* 64, 663-667.

Yushkevich, P.A., Piven, J., Hazlett, H.C., Smith, R.G., Ho, S., Gee, J.C., Gerig, G., 2006. User-guided 3D active contour segmentation of anatomical structures: significantly improved

efficiency and reliability. *Neuroimage* 31(3), 1116-1128.

Figure Legends

Figure 1

Flow chart of patients followed-up 3.5 years later through interview and chart review and subjects lost to follow-up.

Figure 2

Cortical thinning in First Episode Psychosis (FEP) patients versus healthy controls (HC) in the right superior Lateral Temporal Cortex (LTC) after False Discovery Rate (FDR) correction, $p=0.05$. The significance in this display is a $-\log_{10}p$ value.

Figure 3

Regional volume reductions in the caudate of First Episode Psychosis (FEP) patients compared with Healthy Controls (HC) (Top) and regional shape deflation in the right caudate of FEP patients compared with controls after the effect of volume has been removed (Bottom). Includes False Discovery Rate (FDR) correction, $p=0.05$.

Table 1. Demographic characteristics of FEP patients and healthy controls.

		Patients	Controls	p-value
		Mean (SD)	Mean (SD)	t-test / χ^2
Age (years)		28.4 (8.8)	28.6 (8.5)	0.93
Gender (M/F)		n = 32/14	n = 33/13	0.82
Duration Untreated (DUP) (months)		14 (17)		
Days on Medication		18 (16)		
Medication: Total CPZ Equiv (mgs)	Cumulative Daily Dose	4937 (6820) 224 (198)		
Antipsychotic Type:	Aripiprazole Haloperidol None Olanzapine Paliperidone Quetiapine Risperidone	4 1 7 19 3 5 7		
Symptoms: PANSS	Total Positive Negative General	65 (15) 17 (4) 15 (7) 33 (7)		
Symptoms @ Follow Up: PANSS	Total Positive Negative General	43 (13) 9 (3) 11 (6) 22 (6)		
Functionality: GAF	Baseline Follow Up	51 (11) 76 (14)		
Diagnosis: SCID	Non-Affective Affective	n = 31 n = 15		
Severity: USS @ Follow Up	No further episodes Mild Moderate Severe	n = 11 n = 1 n = 11 n = 11		

SD = standard deviation. DUP= duration of untreated psychosis, CPZ= chlorpromazine equivalents, PANSS= positive and negative symptom scale, GAF= global assessment of functioning, SCID = Structured Clinical Interview for DSM Disorders, USS= usual symptom severity.

Table 2. Overall brain structure volumes from the manual segmentation

Structure	Hemisphere	HC (n=46) (mm ³)		FEP (n=46) (mm ³)		GLM*	
		Mean	SD	Mean	SD	F	p
Hippocampus	Left	2990	403	2891	373	1.05	0.308
	Right	3018	400	2909	379	1.33	0.251
Caudate	Left	4935	624	4607	696	5.67	0.019
	Right	5123	609	4748	743	7.40	0.008 \perp
Lateral Ventricle	Left	7241	3743	8204	3123	2.82	0.097 \perp
	Right	6950	3540	7649	2627	1.94	0.167

* Results from a general linear model (GLM) comparing FEP and HC with age and intracranial volume (ICV) as covariates. \perp p<0.05

Table 3. Relationship between structural brain abnormality and clinical variables at baseline and change over a 3 year follow up period

Clinical Variable	Right LTC Thickness		Total Caudate Volume	
	<i>Beta</i>	<i>p</i>	<i>Beta</i>	<i>p</i>
Baseline				
GAF score	0.04	0.80	-0.23	0.26
Medication (CPZ Equivalents)	0.27	0.12	-0.08	0.70
DUP	0.15	0.35	-0.64	0.53
Change				
GAF	-0.47	0.65	-0.26	0.28
PANSS Total	-0.07	0.82	0.15	0.55
PANSS Negative	0.45	0.13	-0.24	0.34
Follow-Up				
USS	0.25	0.93	0.00	0.56
Affective v Non-Affective	-0.18	0.29	0.10	0.44

Model corrected for age and intracranial volume (ICV). LTC = Lateral Temporal Cortex, DUP = duration of untreated psychosis, CPZ= chlorpromazine equivalents, PANSS= positive and negative symptom scale, GAF= global assessment of functioning, USS= usual symptom severity, SCID = Structured Clinical Interview for DSM-IV

Table 4. FEP patients' diagnoses at baseline and follow-up, for patients re-assessed 3.5 years later.

	Baseline	Follow-Up
Patient 1	Bipolar 1 Disorder	Bipolar 1 Disorder
Patient 2	Bipolar 1 Disorder	Bipolar 1 Disorder
Patient 3	Bipolar 1 Disorder	Bipolar 1 Disorder
Patient 4	Bipolar 1 Disorder	Bipolar 1 Disorder
Patient 5	Bipolar 1 Disorder	Bipolar 1 Disorder
Patient 6	Bipolar 1 Disorder	Bipolar 1 Disorder
Patient 7	Bipolar 1 Disorder	Schizophrenia*
Patient 8	Delusional Disorder	Delusional Disorder
Patient 9	Delusional Disorder	Schizophrenia*
Patient 10	Major Depressive Disorder	Major Depressive Disorder
Patient 11	Major Depressive Disorder	Major Depressive Disorder
Patient 12	Major Depressive Disorder	Bipolar 1 Disorder*
Patient 13	Psychotic Disorder NOS	Psychotic Disorder NOS
Patient 14	Psychotic Disorder NOS	Psychotic Disorder NOS
Patient 15	Psychotic Disorder NOS	Bipolar 1 Disorder*
Patient 16	Psychotic Disorder NOS	Psychotic Depression*
Patient 17	Schizoaffective Disorder	Schizoaffective Disorder
Patient 18	Schizophrenia	Schizophrenia
Patient 19	Schizophrenia	Schizophrenia
Patient 20	Schizophrenia	Schizophrenia
Patient 21	Schizophrenia	Schizoaffective*
Patient 22	Schizophreniform disorder	Bipolar 1 Disorder*
Patient 23	Schizophreniform disorder	Psychotic Disorder NOS*
Patient 24	Schizophreniform disorder	Schizoaffective Disorder*
Patient 25	Schizophreniform disorder	Schizophrenia*
Patient 26	Schizophreniform disorder	Schizophrenia*
Patient 27	Schizophreniform disorder	Schizophrenia*
Patient 28	Schizophreniform disorder	Substance Induced Psychotic*

* Denotes patients with a change in diagnosis 3.5 years later.

Figure 1

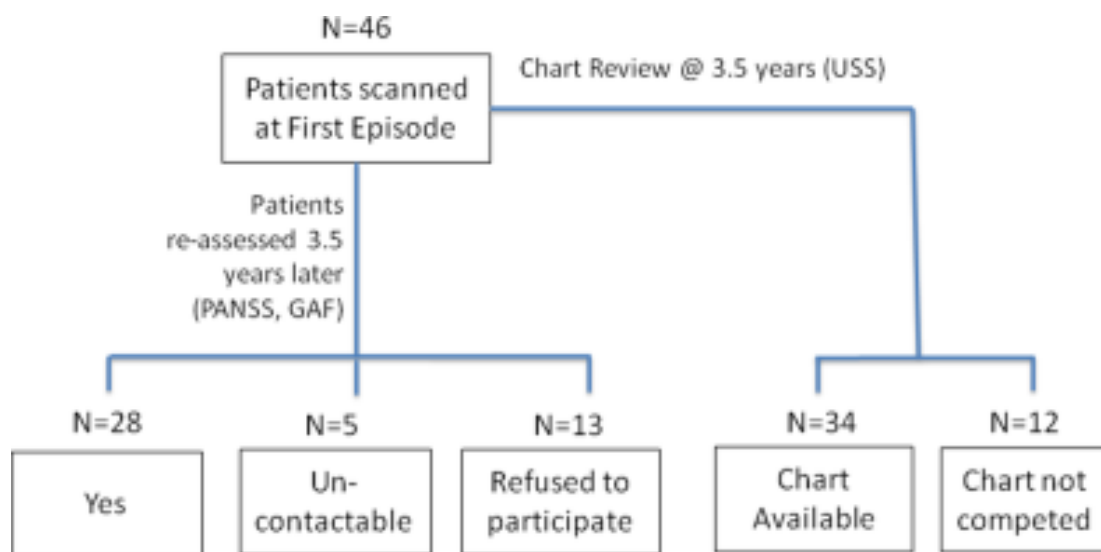
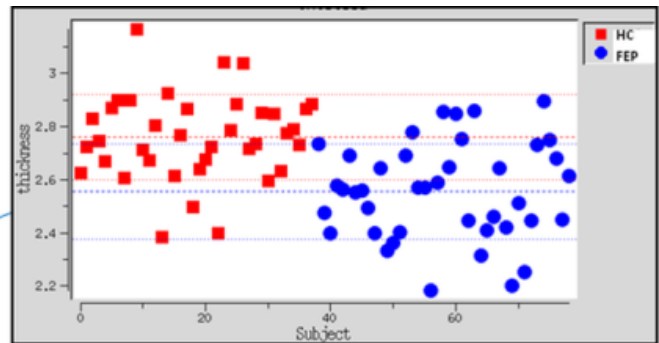
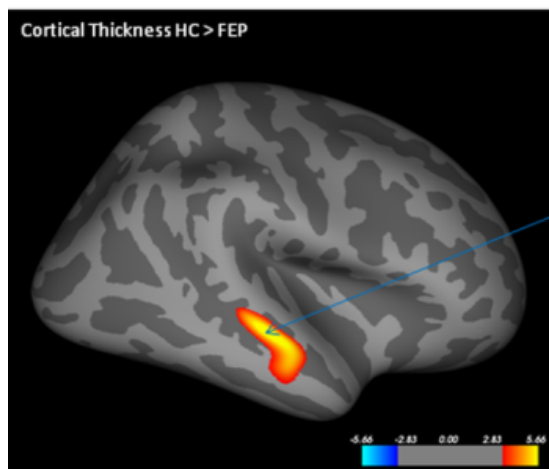


Figure 2



Cluster Region	Max $-\log_{10}(p)$	Size (mm^2)	No. Of Vertices	Tal X	Tal Y	Tal Z
LTC	6.03	626.6	1284	46.6	-21.4	-7.2

Figure 3

