



## **Enlarging neck masses in the elderly - Histological and surgical considerations.**

Title	Enlarging neck masses in the elderly - Histological and surgical considerations.
Author(s)	O'Sullivan MD, McAnena KS, Egan C, Waters PS, McCann PJ, Kerin MJ
Publication Date	2013



## Enlarging neck masses in the elderly – Histological and surgical considerations

M.D. O'Sullivan<sup>a</sup>, K.S. McAnena<sup>a</sup>, C. Egan<sup>b</sup>, P.S. Waters<sup>a</sup>, P.J. McCann<sup>a</sup>, M.J. Kerin<sup>a,\*</sup>

<sup>a</sup> Discipline of Surgery, School of Medicine, National University of Ireland, Galway, Ireland

<sup>b</sup> Department of Pathology, School of Medicine, National University of Ireland, Galway, Ireland

### ARTICLE INFO

#### Article history:

Received 14 December 2012

Accepted 17 December 2012

Available online 17 January 2013

#### Keywords:

Anaplastic carcinoma of thyroid

Fine needle aspiration cytology

Thyroidectomy

P53

### ABSTRACT

**INTRODUCTION:** Anaplastic carcinoma of the thyroid is a rare but aggressive malignancy which can present with a rapidly enlarging neck mass or compressive sequelae of cough, dyspnoea, dysphagia and hoarseness. Treatment of such tumours is commonly palliative however they occasionally represent surgical challenges due to their rapid growth, diagnostic difficulty and locoregional spread.

**PRESENTATION OF CASE:** A 75 year-old retired veterinary surgeon was referred with a 2 month history of a painless, enlarging neck mass. The patient denied any secondary compressive symptoms or general symptoms of malignancy. On examination a large right-sided neck mass measuring 7 cm × 5 cm was appreciated which was fixed, hard and irregular with associated adenopathy.

**DISCUSSION:** We discuss the diagnostic challenges posed by anaplastic carcinoma of the thyroid and the difficulties in selecting the appropriate intervention in this aggressive disease process.

**CONCLUSION:** Anaplastic carcinoma of the thyroid is encountered infrequently in clinical practice and can generate diagnostic and therapeutic challenges.

© 2013 Published by Elsevier Ltd on behalf of Surgical Associates Ltd.

### 1. Introduction

Anaplastic carcinoma of the thyroid is a rare but aggressive malignancy of the head and neck region. In distinction from differentiated carcinoma of the thyroid, anaplastic is classified as undifferentiated carcinoma, heralding its aggressive nature. Clinically the majority of patients will present with a rapidly enlarging neck mass or compressive sequelae of cough, dyspnoea, dysphagia and hoarseness. Histologically the tumour is composed of undifferentiated cells which show immunohistochemical evidence of epithelial differentiation. Expression of usual markers of thyroid origin, such as Thyroglobulin or Thyroid Transcription Factor-1 (TTF-1) is exceptional and diagnosis can prove challenging. Poor prognostic factors include male sex, age over 60, and distant metastasis.<sup>1</sup>

### 2. Case report

A 75 year-old retired veterinary surgeon was referred to a tertiary referral centre with a 2 month history of a painless, enlarging neck mass. The patient denied local symptoms of dysphagia, dysphonia or otalgia and did not report systemic symptoms of weight loss or night sweats. He was an ex-smoker with a 75 pack year history. Clinical examination showed a right-sided neck mass approximately 7 cm × 5 cm in size which extended through both

anterior and posterior triangles of the neck. On palpation the mass was irregular and fixed. Cervical lymphadenopathy was appreciated and the patient was clinically euthyroid.

Routine haematological and biochemical investigations, Calcitonin, Carcinoembryonic antigen (CEA), thyroid function tests (TFTs) and parathyroid hormone levels (PTH) were all within normal limits. A needle core biopsy of the neck mass showed a poorly differentiated spindle cell tumour with large pleomorphic nuclei and abundant abnormal mitoses. A wide panel of immunohistochemistry was carried out to further classify, and the tumour cells were positive for cytokeratin (Fig. 1) (AE1/AE3 and CAM 5.2), vimentin (Fig. 2) and CD 10. Other markers, including TTF-1, thyroglobulin, CK5/6 and p63 were negative. This immunoprofile was consistent with metastatic poorly differentiated sarcomatoid carcinoma and the differential diagnosis included origin from the kidney, lung or thyroid.

This result prompted both magnetic resonance imaging (MRI) of the kidneys and a computed tomography (CT) scan of the thorax, abdomen and pelvis, both of which were non contributory.

To further define the anatomy of the malignant neck mass a CT neck (Fig. 3) was performed. It showed a 6 cm mass suggestive of a right oropharyngeal carcinoma with bulky right-sided neck lymphadenopathy. The follow-up nasal endoscopy was normal. Finally staging was concluded with a positron emission tomography (PET) scan (Fig. 4), which was significant for the right neck lesion but also for a discrete area in the right colon which was 18-fluorodeoxyglucose (18-FDG) avid. On a subsequent colonoscopy this finding on PET proved to be a false positive, with no corresponding abnormality found.

\* Corresponding author. Tel.: +353 91544637.

E-mail addresses: [michael.kerin@nuigalway.ie](mailto:michael.kerin@nuigalway.ie), [peadarwaters@hotmail.com](mailto:peadarwaters@hotmail.com) (M.J. Kerin).

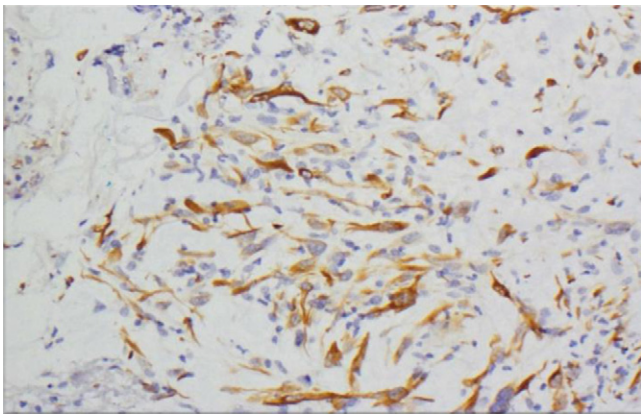


Fig. 1. Cells staining positive with cytokeratin.

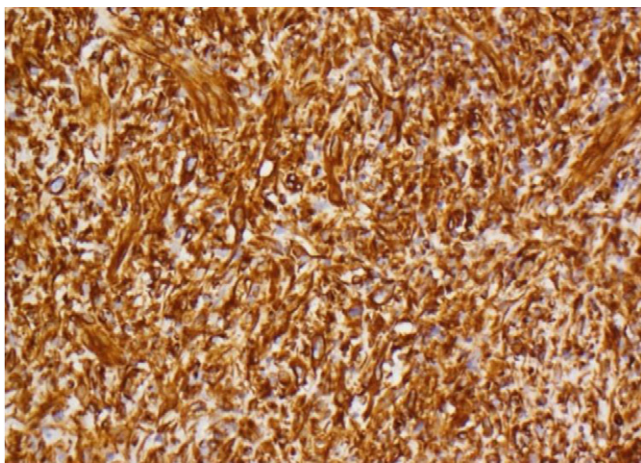


Fig. 2. Cells staining strongly positive with vimentin.

### 3. Surgical dilemma

The case was discussed at the Head and Neck Multidisciplinary Meeting (MDM). Given the apparent absence of any further lesions on radiological scans and based on the anatomy of the lesion, it was decided that the appropriate management was a right level V neck dissection with removal of the mass.

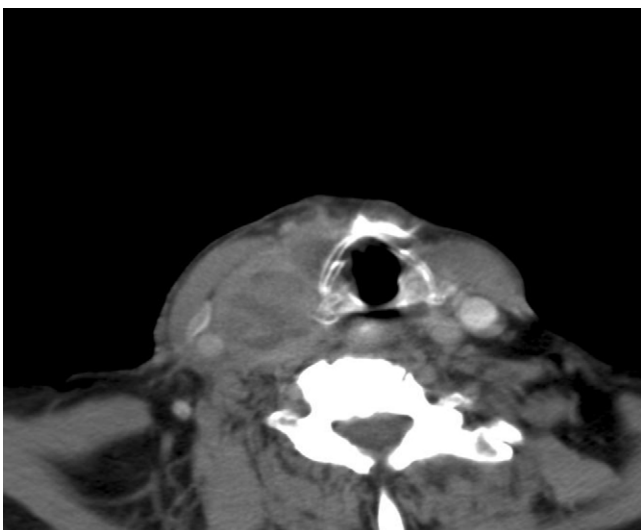


Fig. 3. Cross-sectional CT image of the right neck mass.

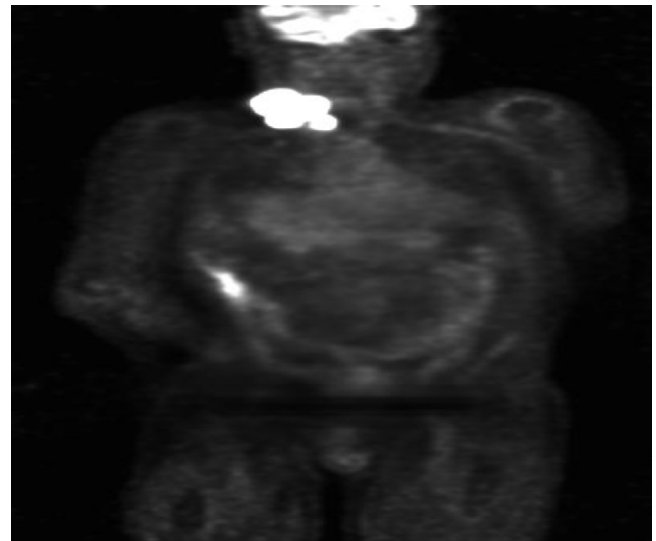


Fig. 4. Coronal PET scan displaying 18-FDG avid neck mass and right colon.

Intraoperatively, following the removal of the neck mass, it was noted that there was enlargement of the right lobe of the thyroid. An intraoperative consultation was requested from the endocrine surgical team, and an on-table FNA was performed for cytological examination. Subsequently the patient had uncomplicated operative and post operative course.

The on-table FNA of the right thyroid lobe showed a malignant, highly cellular specimen with numerous pleomorphic tumour cells, including bizarre giant cells and mitotic figures.

The excised neck mass had a lobulated appearance and was approximately 70 mm in maximum dimension (Fig. 5). Histological examination showed a high grade tumour composed of spindle cells and giant cells extensively replacing lymph nodes and soft tissue in the neck. The morphology and immunophenotype was similar to the previous core biopsy, with tumour cells positive for cytokeratin and vimentin. TTF-1 and Thyroglobulin were negative. In conjunction with the results of the FNA, this was interpreted as metastatic anaplastic carcinoma arising within adjacent thyroid gland, in which loss of expression of typical immunohistochemical markers of thyroid origin is usual.

The case was referred to the endocrine surgical team for further management. At this point in time the case presented a surgical dilemma, with both indications and contraindications for a total thyroidectomy. Operative indications included a focus of malignancy in the right lobe of the thyroid, however given the diagnosis of anaplastic carcinoma and the local extent of the tumour it would

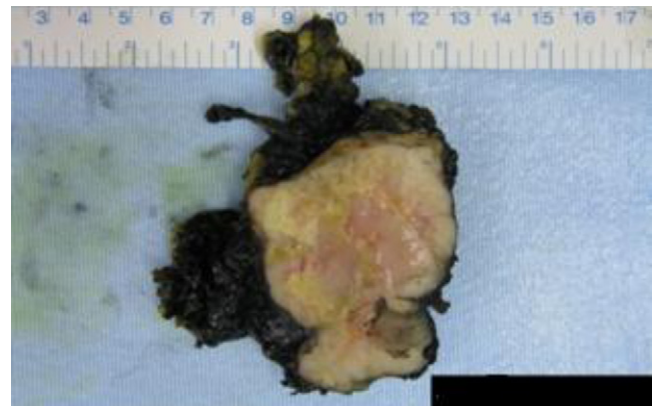


Fig. 5. Gross specimen of dissected lymph node containing anaplastic carcinoma.

be classified as stage IVB (extrathyroidal spread without distant metastases). Currently in the literature surgical intervention at this stage is controversial.<sup>2,3</sup>

The case was discussed at the thyroid cancer MDM and it was decided that the best management included a total thyroidectomy and adjuvant radiotherapy. This operation was undertaken one month after the initial Level V neck dissection. Intraoperatively the right lobe of the thyroid was grossly enlarged, extending posteriorly to the oesophagus and inferiorly to the subclavian vein. The right recurrent laryngeal nerve was involved in the tumour and was formally divided. The left lobe of the thyroid was grossly normal. The thyroid was excised without further complication. The left parathyroids were visualised and preserved. The patient was initiated on oral calcium and levothyroxine postoperatively, had an uncomplicated recovery from surgery, and was discharged in the following six days.

Histology of the excised thyroid gland showed a tumour, 73 mm in size, composed of both anaplastic carcinoma and papillary carcinoma with follicular variant. Hashimoto's thyroiditis was present within the remaining thyroid parenchyma. There was extension of the tumour into the soft tissue and fat around the thyroid.

Despite surgery and a referral for adjuvant radiotherapy, the patient died nineteen weeks post-operatively.

#### 4. Discussion

The differential diagnosis of a neck mass is extensive and varies with age. This case described a rare cause of a neck mass, with anaplastic carcinoma of the thyroid having an age-adjusted annual incidence of two per million persons.<sup>4</sup> It is one of the most aggressive neoplasms known to medicine. In this case, the site of the primary tumour proved elusive and immunohistochemistry could only generate a differential diagnosis for potential primary sites. Radiological investigations were ineffective, with the CT neck characterising the mass as potentially sarcomatous and oropharyngeal in origin. Ultimately, it was during intraoperative inspection of the surgical site after the dissection of the neck mass, that the primary lesion within the thyroid was discovered, and confirmed cytologically.

Due to the extensive involvement of the cervical soft tissue, the tumour was staged retrospectively as IVB, extrathyroidal spread without distant metastases.

#### 5. UICC stage IV: subdivision<sup>5</sup>

IVA	Tumour limited to thyroid
IVB	Tumour with extracapsular extension
IVC	Tumour presence of distant metastasis

Currently there is debate in the literature as to at what stage surgical intervention is indicated. A study by McIver et al., showed a cohort of patients suffering from anaplastic carcinoma had no benefit in survival following surgical resection of the tumour.<sup>6</sup> It must be noted, that in this study 46% of the included cohort had evidence of metastatic disease at the time of diagnosis and were therefore stage IVC. In contrast, a study by Haigh et al showed a survival advantage following resection of localised tumour combined with postoperative adjuvant chemoradiotherapy, even with persistent minimal disease on vital structures.<sup>7</sup> Recently it has been shown that subdividing stage IVB could have both therapeutic and prognostic significance,<sup>8</sup> suggesting that the degree of extracapsular extension is clinically important.

The excised thyroid tumour was composed of both anaplastic and papillary carcinoma. This finding highlights the pathogenesis

of anaplastic tumours. Through dedifferentiation, the cells of a papillary carcinoma change to those of an anaplastic carcinoma, evident histologically as epithelial–mesenchymal transition. Genetically this conversion is driven by mutations of p53 tumour suppressor gene, which is found at high frequency in anaplastic carcinoma.<sup>9</sup> In vitro studies have exploited this fact, and have employed adenovirus as a vector for gene therapy, reintroducing p53 tumour suppressor gene to anaplastic cells and subsequently improving their chemosensitivity.<sup>10</sup> Other possible novel therapies include peroxisome proliferator-activated receptor gamma (PPAR $\gamma$ ) agonists, which have been shown to induce apoptosis in anaplastic cancer cell lines.<sup>11</sup> Clinically a recent case report has shown a patient with gross residual disease following resection of anaplastic carcinoma has had 18 months of complete response with the addition of sunitinib, a tyrosine kinase receptor inhibitor, to chemoradiotherapy.<sup>12</sup>

In this case we would like to emphasise the diagnostic challenge posed by anaplastic carcinoma of the thyroid and the difficulty in selecting the appropriate intervention in this aggressive disease process.

#### Conflict of interest statement

None.

#### Funding

None.

#### Ethical approval

Written informed consent was obtained from the patient for publication of this case report and accompanying images.

#### Author contributions

M.D. O'Sullivan and K.S. McAnena contributed toward writing of the manuscript; P.S. Waters contributed toward revision of manuscript; C. Egan contributed toward the histopathological aspects of the case. P.J. McCann and M.J. Kerin carried out a final review on the manuscript prior to submission.

#### References

- Kebebew E, Greenspan FS, Clark OH, Woeber KA, McMillan A. Anaplastic thyroid carcinoma. Treatment outcome and prognostic factors. *Cancer* 2005;**103**(7):1330.
- Sherman SI. Thyroid carcinoma. *Lancet* 2003;**361**(9356):501–11.
- Wein RO, Weber RS. Anaplastic thyroid carcinoma: palliation or treatment? *Current Opinion in Otolaryngology and Head and Neck Surgery* 2011;**19**(April (2)):113–8.
- Mazzaferrri EL. Undifferentiated thyroid carcinoma and unusual thyroid malignancies. In: *Endocrine tumors*. Boston: Blackwell Scientific Publications; 1993. p. 378.
- Ito Y, Higashiyama T, Hirokawa M, Fukushima M, Yabuta T, Tomoda C, et al. Investigation of the validity of UICC stage grouping of anaplastic carcinoma of the thyroid. *Asian Journal of Surgery* 2009;**32**(January (1)): 47–50.
- McIver B, Hay ID, Giuffrida DF, Dvorak CE, Grant CS, Thompson GB, et al. Anaplastic thyroid carcinoma: a 50-year experience at a single institution. *Surgery* 2001;**130**(December (6)):1028–34.
- Haigh PI, Ituarte PH, Wu HS, Treseler PA, Posner MD, Quivey JM, et al. Completely resected anaplastic thyroid carcinoma combined with adjuvant chemotherapy and irradiation is associated with prolonged survival. *Cancer* 2001;**91**(12):2335–42.
- Ito KI, Hanamura T, Murayama K, Okada T, Watanabe T, Harada M, et al. Multimodality therapeutic outcomes in anaplastic thyroid carcinoma: improved survival in subgroups of patients with localized primary tumors. *Head and Neck* 2011, <http://dx.doi.org/10.1002/hed.21721>.
- DeLellis RA. Pathology and genetics of thyroid carcinoma. *Journal of Surgical Oncology* 2006;**94**(8):662–9.

10. Blagosklonny MV, Giannakakou P, Wojtowicz M, Romanova LY, Ain KB, Bates SE, et al. Effects of p53-expressing adenovirus on the chemosensitivity and differentiation of anaplastic thyroid cancer cells. *Journal of Clinical Endocrinology and Metabolism* 1998;**83**(July (7)):2516–22.
11. Miccoli P, Materazzi G, Antonelli A, Panicucci E, Frustaci G, Berti P, et al. New trends in the treatment of undifferentiated carcinomas of the thyroid. *Langenbeck's Archives of Surgery* 2007;**392**(July (4)):397–404.
12. Schoenfeld JD, Odejide OO, Wirth LJ, Chan AW. Survival of a patient with anaplastic thyroid cancer following intensity-modulated radiotherapy and sunitinib—a case report. *Anticancer Research* 2012;**32**(May (5)):1743–6.

#### Open Access

This article is published Open Access at [scimedirect.com](http://scimedirect.com). It is distributed under the [IJSCR Supplemental terms and conditions](#), which permits unrestricted non commercial use, distribution, and reproduction in any medium, provided the original authors and source are credited.